



---

---

## Programmed cell death in neurodegenerative brain disease

A.L. Okwi<sup>a\*</sup>, A. Parkes<sup>b\*</sup>

<sup>a</sup>Department of Pathology, Medical School, Makerere University, P.O. Box 7062 Kampala, Uganda.

<sup>b</sup>A. Parkes, University of Wales Institute Cardiff, Cardiff CF 14 4XW, UK

\*Correspondence: livex@yahoo.co.uk

---

### Abstract

Death of brain cells by either apoptosis or necrosis is the hall mark of the pathology of most brain infections such as Alzheimer's disease and AIDS dementia. The death of astrocytes in association with brain tumours appears to be an insignificant event. Detection of apoptosis in human brain tissues fixed in 10% buffered formalin and embedded in paraffin wax was determined in the Department of Medicine, in conjunction with the Department of Dermatology, University of Wales College of Medicine using three selected methods, namely Heamatoxylin and Eosin (H and E) which intensely stains the nuclei of apoptotic cells dark, Methyl Green Pyronin (MGP) which stains the nuclei of apoptotic cells deep pink purple and terminal deoxynucleotidyl transferase uridine nick end labeling (TUNEL) method which stains the DNA fragments of apoptotic cells dark brown. By looking at changes in the cell nuclei, together with mRNA levels in the cytoplasm and also by analyzing DNA fragments in situ, evidence of apoptosis was found both in neurons and astrocytes. The type and number of brain cells that died from apoptosis varied from case to case. Apoptosis was not detected in normal aging brain control.

---

### Introduction

Programmed cell death is a phenomenon which occurs in most of the cell types of the body and brain cells are no exception. Programmed cell death now commonly known as apoptosis was formerly known as 'Collucillman bodies or Shinkage Necrosis'<sup>1</sup>. According to Richards and colleagues the most noticeable change in the appearance of the nucleus is that the chromatin with its associated proteins which is usually dispersed, condenses into one or more distinct bodies near the nuclear membrane<sup>2</sup>. There is also an increase in messenger ribonucleic acid (mRNA) levels in cells undergoing programmed cell death.

Programmed cell death is becoming increasingly recognized as an important event in the nervous system development and disease<sup>3</sup>. It has been suggested that the ligands such as neutrophin 3 (NT-3), brain derived factor (BDF) and nerve growth factor (NGF) are involved in neuronal cell death<sup>4</sup>. Withdrawal of these factors has been linked to the death of neurons by programmed cell death with the possible emergence of neudegenerative brain diseases such as Alzheimer's and AIDS dementia. For example sympathetic neurons of embryonic rats which grew in the presence of neutophin factor died by programmed cell death on withdrawal of this factor<sup>5</sup>. Likewise neuronally differentiated PC 12

cells of rat culture underwent synchronous apoptosis when deprived of NGF<sup>6</sup>. (Schulz 1997). In other related experiment, neuronal cells of embryonic rat retinal ganglion were rescued from apoptosis when cultured in the presence of Brain Derived Factor (BDF)<sup>7</sup> and neurotrophin 3 (NT-3) prevented the death of facial motor neurons by apoptosis in new born rat<sup>8</sup>. Some of the studies have sowed that death of the neurons may be due to death of the astrocytes by human immunodeficiency virus (HIV). The activation of the rat astrocytes channels by HIV glycoprotein 120 (gp120) mediated by sodium and hydrogen ions exchange stimulation, led to the depolarization and activation of voltage-sensitive calcium ion channels in astrocytes with eventual death of the cells<sup>9</sup>.

The evidence for the death of brain cells is rather limited in that relatively few species or systems have been examined, although experimental studies to demonstrate programmed cell death have been going on for sometime. Most of these experiments have based their findings on the use of animal and culture models. It therefore appears that less emphasis has been put on the use of human brain tissues in these experiments. This study therefore sought to use human brain tissue to determine whether there is any association between apoptosis and neurodegenerative brain disease.

**Materials and Methods**

The equipment and material required for the project were provided by the Departments of Medicine, Dermatology and Pathology, University of Wales College of Medicine.

Sodium acetate trihydrate and methyl green were supplied by BDH Limited Poole England. Glycerol, Tris (hydroxymethyl)-methylamine (Tris buffer), sodium dihydrogen orthophosphate and di-sodium hydrogen orthophosphate blocking solution, 0.3% hydrogen peroxide in methanol were supplied by a Fisher Scientific International Company. Apotag Kit for TUNEL was supplied by ‘Boehringer Mannheim’ and Protease K 20 µg/ml in 10 mM Tris/Hcl pH 7.4-8.0 was supplied by Sigma Company.

Already processed paraffin wax embedded post mortem human brain tissues were retrieved from the department of Pathology, University of Wales archives with the permission of Dr. Jim W Neal, consultant Pathologist. Seven test cases were of Alzheimer’s disease; three from HIV infected brain and four from brain tumours.

**Results**

**Aging normal brain**

Haematoxylin and Eosin staining of the section from the cortex of a normal ageing brain showed no evidence of apoptosis by TUNEL method (fig1) and by all other methods ((not shown).

**Alzheimer’s disease**

**AIDS dementia**

In AIDS dementia, many astrocytes were demonstrated from the cortex by all the three methods which were possibly dying from apoptosis (fig. 3a, 3b and 3c)

Diagnosis had already been confirmed by histology and all tissue blocks were from the cortex area of the brain. Normal aging brain tissue was also included in the study as a control.

Brain tissue blocks were cooled on ice for 30 minutes, trimmed on Bright microtome to expose the cutting surface and serial sections were cut at 5 microns (µ) thickness. These were floated on 20 percent ethanol and lowered on a water bath kept at 42°C. Sections were picked up on clean glass slides and put on a hot plate at 52°C. Finally the sections were kept in a drying oven at 43-45°C overnight.

The serial sections from each case were stained by the following selected methods namely: - Haematoxylin and Eosin and Methyl Green Pyronin adapted after Bancroft and Cook<sup>10</sup>. TUNEL adapted from In situ Cell Death Detection Kit (Enzo)

All the three methods demonstrated apoptotic cells in Alzheimer’s disease. In H and E method, there were intensely stained nuclei surrounded by ‘halo’ which was characteristic of apoptotic cells (fig 2a). The cells stained deep pink purple by methyl green pyronin which was indicative of apoptosis (fig 2b). TUNEL reaction method showed dark brown stained terminal deoxynucleotidyl transferase labeled apoptotic neurons (fig 2c).

**Brain tumour (astrocytoma)**

Few tumour cells (astrocytes) probably dying from apoptosis were demonstrated by H and E (fig 4) and by all other methods (figures not indicated).

**Table I showing the location and intensity of apoptosis in neurodegenerative diseases**

CASES	METHODS			LOCATION
	H and E	MGP	TUNNEL	
Normal aging brain	Negative	Negative	Negative	-
Alzheimer’s	Positive	Positive	Positive	Neurons
AIDS dementia	Positive	Positive	Positive	Astrocytes
Brain tumour	Positive	Positive	Positive	Astrocytes




Figure 1

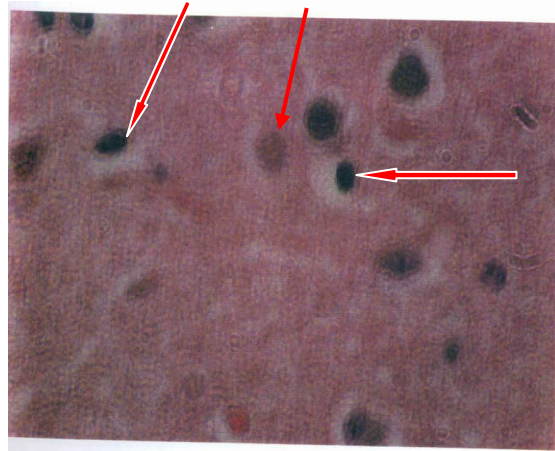


Figure 2A

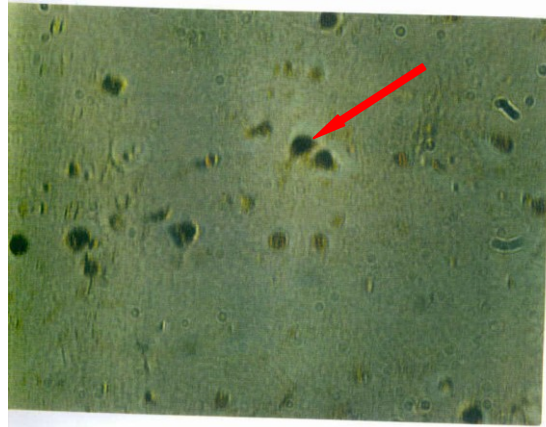
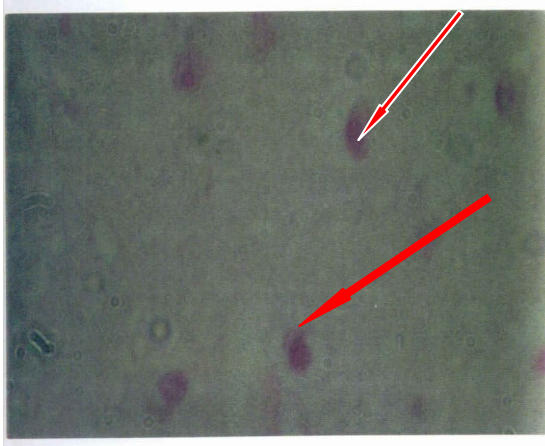


Figure 1: TUNEL staining of a section from the cortex of normal ageing brain, x 10 magnification. Figure 2: (A) Haematoxylin and eosin staining of the neocortex showing some of the intensely dark stained nuclei surrounded by ‘a halo’ characteristic of apoptosis (see big arrow) small arrow shows normal cells (B) Methyl

green pyronin staining of the same neurons showing deep pink-purple colour surrounded by ‘a halo’ characteristic of apoptosis (see arrows) Magnification x100. (C) The same neurons stained dark brown by TUNEL method characteristic of apoptosis (see arrow) Magnification x100

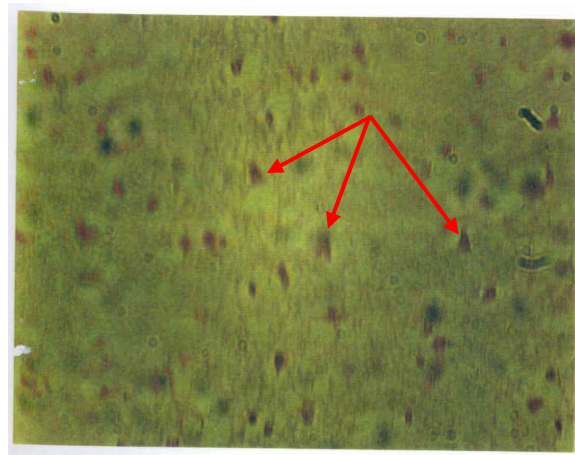
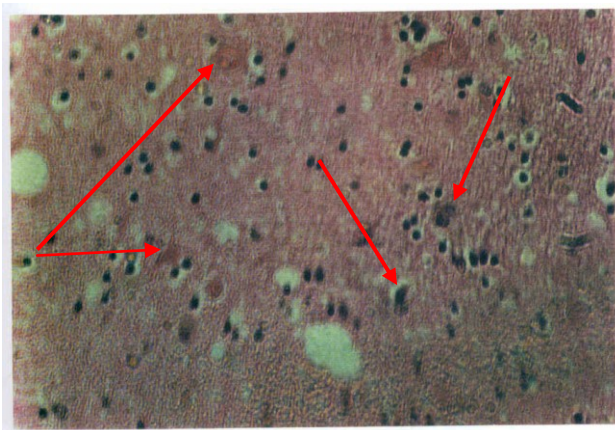


Figure 3A

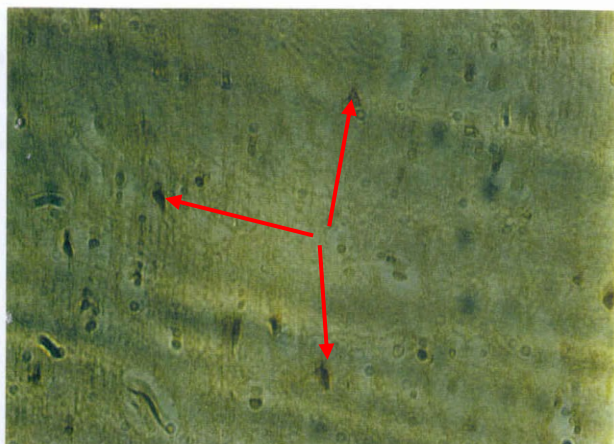
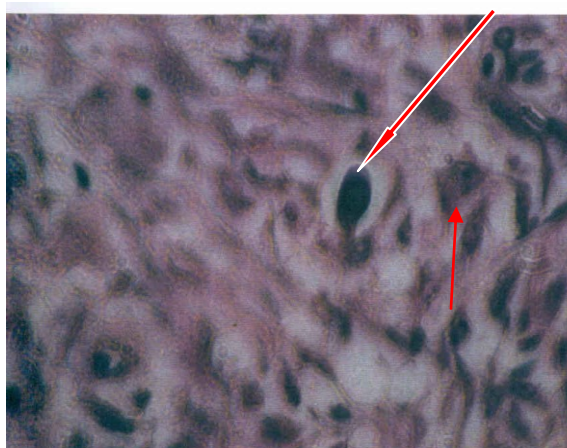


Figure 3 (A) H and E staining of the sections from the cortex in AIDS dementia showing darkly stained nuclei, some of which are surrounded by 'a halo' (see arrows on the right) These were probably apoptotic nuclei and the cells were probably astrocytes. Arrows on the left show lightly stained normal cells. Magnification x 50). (B) Methyl green pyronin

Figure 3B



staining showing deep pink-purple stained cells which is characteristic of apoptosis (see arrows). These cells were possibly astrocytes or gial cells. (Mag x50. (C)The same cells stained intensely dark brown by TUNEL which is characteristic of apoptosis (see arrows).

## Discussion

The process of apoptosis or programmed cell death, is, a normal function of the cell. The mechanism exists to limit the disruption to the organism which would be caused by the prolongation of the life of a cell which was old or malfunctioning. However, one could envisage that a malfunction in the mechanism controlling apoptosis could itself lead to disease. For instance, the inhibition of apoptosis in a malignant tissue would lead to uncontrolled growth of a tumour. Conversely uncontrolled apoptosis could lead to a loss of cells, for example, in a condition such as AIDS.

The brain would be no exception to this. There is already evidence to suggest that neurodegeneration could be linked to apoptosis and the ageing process. However, an experimental approach to study these phenomenons in human would not be possible. One source of experimental material which could be used would be archive tissues blocks taken from the brain at postmortem examination. However, methods of removal, storage and fixation often render these tissues unsuitable for the more sophisticated immuno and molecular biological staining procedures. The primary aim of this study was to seek evidence of apoptosis in the human-brain cortex taken at postmortem, fixed

with 10% formalin and paraffin embedded. Three staining procedures were used: the haematoxylin and eosin technique which was used to stain the condensed chromatin and the Methyl Green Pyronin method which was used to look for changes in the DNA and in the nucleus and RNA in cytoplasm of the cells. Using this technique, changes in the appearance of the nucleus and cytoplasm in the cells of the brain tissues studied were detailed and interpreted as suggestive of apoptosis. The third technique used commercial procedure called TUNEL which monitors the degree of DNA fragmentation, a process closely associated with the biochemical changes associated with apoptosis.

In order to compare and contrast the study pattern seen with these methods, tissues from several contrasting brain pathologies were studied. Firstly, tissue blocks were available from a case where the brain showed no pathology these were regarded as 'normal ageing brain' and were used as a base line for the investigation. Tissue blocks from brain tumours were also available. All these tumours were malignant astrocytomas. The remaining blocks were from Alzheimer's disease and AIDS dementia.

Cell death by apoptosis in normal ageing brain appears to be an insignificant process. In this study, it was shown that there were no cells dying from apoptosis in the normal aging brain sample that was used as a base line control for the study. One could probably say that even if apoptosis process is going on in ageing brain, it may be so slow that the cells that undergo apoptosis are quickly removed from the vicinity by macrophages leaving the brain free of apoptotic cells and making it difficult to detect apoptosis. In this case the best way would probably be by detecting apoptotic bodies in macrophages in a normal ageing brain. This may account for the reason why according to Morison and Hof apoptosis mechanism in aging is not associated with age-related impairment of neocortical and hippocampal function observed in Alzheimer's disease<sup>11</sup>.

Many neurons in Alzheimers disease exhibited terminal deoxynucleotidyl transferase labeling for DNA typical of apoptosis. These results agree with the findings of other authors, in that excessive death of neurons was demonstrated in association with Alzheimer's disease in the cortex region of the brain<sup>12,13</sup>. Why this was so was difficult to explain. Many neurons were affected in Alzheimer's disease probably because they were within the locality of amyloid deposits or were affected by neurofibrillary

## Conclusion

The study demonstrated that apoptosis occurs in the human brain in both neurons and astrocytes, in different conditions such as Alzheimer's, disease, HIV dementia and brain tumours. The study also showed that more neurons die by apoptosis in Alzheimer's disease than in any other neuropathological condition. From this study it has also been noted that astrocytes are more compromised in HIV dementia than in brain tumours of glial cell origin and the death of astrocytes by apoptosis in glial cell brain tumours appears to be a slow process as observed in the study. From the study it could be said that programmed cell death in a normal ageing brain appears to be insignificant. The study has equally proved that the methods that were used can be relied on for the detection of apoptosis inspite of their limitations.

degeneration involving mutation of presenelin genes<sup>14,15,16,17</sup>.

In this study, apoptosis was also demonstrated in astrocytes in both malignant astrocytomas. It was also noted that many astrocytes were dying by apoptosis in AIDS dementia. This observation has equally been made by Gullemin and colleagues in which the death of many astrocytes by apoptosis was found to play a potential role in AIDS dementia<sup>18</sup>. It was equally found that more astrocytes died by apoptosis in AIDS dementia than in brain tumours. Why this was so was difficult to elucidate. However some hypotheses were used to try and explain this cause. One reason could be that the death of astrocytes in the brain tumours probably involved an independent apoptotic mechanism. Secondly it was imagined that probably the anti-apoptotic genes (proto-oncogenes) such as bcl-2 were more expressed in brain tumours than in AIDS dementia, and pro-apoptotic genes (tumour suppressor genes) such as wild type p53 were more expressed in AIDS dementia than in brain. This therefore needed further experiments to be done. However since a few cases were available for the study, it was difficult to come up with concrete supporting evidence to substantiate some of these findings. Likewise the study only covered the cortex area of the brain and it was therefore difficult to compare and contrast the occurrence of apoptosis in different areas of the brain.

## Recommendations

Further studies are needed to elucidate apoptosis mechanism in brain cells in other parts of the brain. This may pave away for future application of apoptosis in the treatment and control of these disorders.

## Acknowledgements

I would first of all like to thank Prof I.D. Bowen, Dr. Arthur Parkes, Dr Edwards, Mulcolm and Dr. Jim Neal all of University of Wales Cardiff for the advise they gave me during this study. My acknowledgment also goes to the Makerere University for giving me the opportunity to go to University of Wales for this study. Last but not least I would also like to thank. Prof Wilson Byarugaba and Associate Prof. Ocaido Michael for their guidance during the production of this manuscript.

## References

- 1) Bowen, I.D., Bowen S.M., and Jones, A.H. 1998. Mitosis and Apoptosis. Matters of Life and Death: First Ed. Published by Chapman and Hall, 2-6 Boundary Row, London SE, 8HN . 1998.
- 2) Richards, D.C; Ojuis, D.M; Young D.M. 1996. Cell suicide in Health and Disease. Scientific American 275: 48-55.
- 3) Rubin, L.L. 1997. Neuronal cell death: When, Why, and How. British Medical Bulletin Vol 53 No3 Pages 617-631.
- 4) Decwerth, T.L; Johnson, E.M. Jr 1993. Molecular Mechanisms of Developmental Neuronal Death. In Annual Review of Neuroscience. Ed. Bownie R. Meyer. Printed in USA. Vol 16 Pages 31-46.
- 5) Martin, P.D., Robert, E.S., Peter S.D., Oliver H.L., Loyce G.C. and Eugene M.J.-Jr. (1988). Inhibitors of Protein Synthesis and RNA Synthesis Prevent Neuronal Death Caused by Nerve Growth Factor Deprivation. Journal of Cell Biology Vol 106: Pages 829-844.
- 6) Schulz, J.B., Michael, W; Thomas K.1996. Potassium Deprivation-Induced Apoptosis of Cerebellar Granule Neurons. A sequential Requirement for New mRNA and Protein Synthesis, ICE-Like Protease Activity and Reactive Oxygen Species. The Journal of Neuroscience Vol 16: (15) Pages 4696-4706.
- 7) Hoffer, M.M; Barde, Y.A. 1988. Brain derived neurotrophic factor prevents neuronal death in vivo. Nature Vol 331: Pages 261-265.
- 8) Ernes, T.A; Perssons, H. 1994. Neurotrophin-3 prevents the death of adult central noradrenergic neuron in vivo. Nature. Vol 367: Pages 368-371.
- 9) Rubien, J. K; Benviste, E.N; Benson, D.J.1995. HIV-gp120 activates large conductance apamin-sensitive potassium channels in rat astrocytes. American Journal of Physiology 268: (Cell Physiology) C 1440-1449.
- 10) Bancroft, J.D; Alan, S. 1990. Third Edition Theory and Practice of Histological Techniques. Churchill Livingstone.
- 11) Morrison, J.H; Patrick R.H. 1997. Life and Death of Neurons in aging Brain. Science Vol 273: Pages 412-419.
- 12) Shellenberg, G.D. 1995. Genetic dissection of Alzheimer's disease, a heterogeneous disorder. Proceedings of National Academy of Science USA Vol 92: Pages 8552-8559.
- 13) Le-Blanc and Andrea, C. 2005.. The role of apoptotic pathway in Alzheimer's disease neuro-degeneration and cell death. Current Alzheimer's Resaerch Vol 2: (4) pages 389-402.
- 14) Jinhei Li; Min Xu; Hui Zhou; Jianyi Ma; Huntington, P. 1997. Alzheimer's Presenilin in the Nuclear Membrane, Interphase Kinetochores Suggest a role in Chromosome Segregation. Cell Vol 90: Pages 917-927.
- 15) Mattson, M.P; Partin, J; Bergley, J.G. 1998. Amyloid beta peptide induces-related events in synapses and dendrites. Brain Res Vol 807: 167-176.
- 16) Yihong, Y; Mark, E; Fortini. 1999. Apoptotic Activity of Wild type and Alzheimer's Disease related mutant-Presenilins in Drosophilla melanogaster. Journal of Cell Biology Vol. 146: (6) pages 1351-1364.
- 17) Orly, L; Peterson, L.D; Peterson, D.A; Sangram, S.S. 2006. Expression of a familial Alzheimer's disease -limited presenilin-v variant enhances perforant pathway lesion-induced neuronal loss in the entorhinal cortex. Journal of neuroscience Vol 26: (2) 429-434.
- 18) Gullemin, G.J; Wang, L; Brew, B.J. 2005. Quinolic acid selectively induces apoptosis of human astrocytes: potential role in AIDS dementia complex. Journal of neuroinflammation. <http://www.jneuroinflammation.com/content/2/1/06>